

MANAGEMENT OF CORNEAL EROSIONS DUE TO CHEMICAL BURN BY DURVADI GHRITAM: A CASE STUDY

Jadhav Nandini M^{1*}, Auti Swapnil S², Sreeja Sukeshan³, Mourya OPS⁴

1. P.G. Scholar, Dept. of Salakyatantra, Govt. Ayurveda college, Tripunithura, Kerala, India.
2. Ph.D. Scholar, Dept. of Panchakarma, I.P.G.T. & R.A., Gujarat Ayurved University, Jamnagar, Gujarat, India.
3. Associate Professor, Dept. of Shalakyatantra, Govt. Ayurveda college, Tripunithura, Kerala, India.
4. Professor, Dept. of Ophthalmology, Institute of Medical Sciences, Banaras Hindu University, Varanasi, Uttar Pradesh, India.

Received: 11.07.2012; Revised: 06.08.2012; Accepted: 10.08.2012

Abstract

The tremendous treatment approach in wound healing is aimed at its cosmetic correction and remains as same even when it occurs in a delicate structure like cornea. The aseptic Ayurvedic healing of a wound in an eye, especially in the cornea stills remains as a challenge owing to several reasons. This article explores safe and effective management of corneal erosions in a short period of time. This study explains, a case of a 41 yrs old patient having corneal superficial epithelial erosions due to chemical burn successfully treated with simple and cost effective combination of Durvadi Ghritam and honey following eye pad and bandage for four days. The results confirmed that the drug under trial not only prevents infection but it promotes epithelization and complete healing in shorter duration.

Key words: Durvadi Ghritam; Corneal erosions; Chemical burn; Savrana Shukra; Ashchyotana.

***Address for correspondence:**

Dr. Nandini M. Jadhav,
P.G. Scholar, Dept. of Salakyatantra,
Govt. Ayurveda college, Tripunithura, Kerala, India.
E-mail: nandini.punarvasu17@yahoo.com

INTRODUCTION

Eye burns are one of the most common eye emergencies worldwide, and represent 7% to 18% of eye trauma seen at emergency departments in the US (Melsaether), of these, 84% are caused by chemical agents.^[1] Because of its potential to permanently impair vision or perforate the eye, a chemical burn is considered as an ophthalmologic emergency.^[2]

As many as 20% of chemical injuries result in significant visual and cosmetic disability; only 15% of patients with severe

chemical injuries achieve functional visual rehabilitation.^[3]

In Ayurveda corneal erosions can be compared with Savrana Shukra and is said to be treatable when it is devoid of any discharge and not too deep.^[4] Ocular burns are an ophthalmic emergency requiring immediate irrigation of the eye(s) with copious quantities of sterile saline (preferred) or cold tap water (if sterile saline is not available). Analgesics, topical anesthetics, eye drops to restrict movement of eye muscles (cycloplegics), Placement of a therapeutic bandage and

contact lens until the epithelium gets regenerated can be helpful.^[5] This case study focuses certain useful aspects for rationale use of Durvadi Ghritam in corneal erosion due to chemical burn.

CASE REPORT

A 41 yr old male patient presented to Government Ayurvedic hospital Tripunithura on 24/6/11 with chemical burn by latex of cactus on 23/6/2011 to right eye with complaints of headache, pain in eye, severe burning sensation, gritty sensation, photophobia and blurred vision.

No significant abnormalities were found on physical examination. Ophthalmic examination of the left eye was unremarkable. However, the right eye exhibited mildly swollen lid with congested palpebral conjunctiva along with conjunctival and mild circumcorneal congestion. Direct and indirect pupillary light responses were also normal. The pupil was dilated, the anterior chamber was clear. Fundus was not viewed due to hazy cornea and as the patient was not cooperative. Corneal examination by biomicroscopy revealed diffuse epithelial erosions. Ophthalmic investigation confirmed diagnosis of corneal erosions particularly by positive fluorescein staining test. (Figure 1) Visual acuity was disturbed in right eye which was found to be 1/60; however that of left eye was normal. (Table-1)

Durvadi Ghritam (Table 2) was prepared by classical Snehapaka-Vidhi^[6] using Goghrita (cow ghee), Durva (*Cynodon dactylon*) Swarasa, Yashtimadhu (*Glycyrrhiza glabra*) Kalka and cow milk. On 24/6/11 patient was treated with distilled water Sekam, then Durvadi Ghrita + honey Ashchyotana and pad bandage; however no systemic medication was given to the patient. Visual acuity was found to be improved on 2nd and 3rd day (Table 1) with relief of acute symptoms. On Day 4, this

study observed complete disease remission confirmed by fluroscein staining which was negative, cornea clear (Figure 2) with 6/6 vision. (Table-1) Corneal examination by biomicroscopy revealed complete resolution of conjunctival and circumcorneal congestion. At initial clinical presentation with corneal erosion due to chemical burn patient was having blurred vision with severe symptoms and after Durvadi Ghrita Ashchyotana he was relieved completely with no complications.

Table 1: Improvement in visual acuity

Day	Date	Visual Acuity	
		Right Eye	Left Eye
1 st	24/6/11	1/60	6/6
2 nd	25/6/11	6/24	6/6
3 rd	26/6/11	6/24	6/6
4 th	27/6/11	6/6	6/6

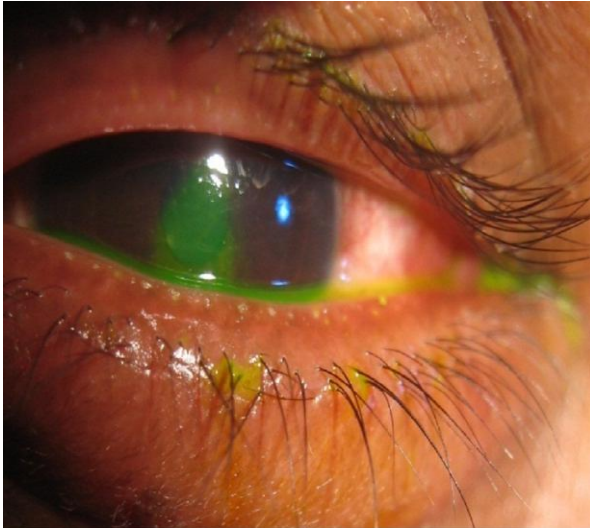
Table 2: Contents used for preparation of Durvadi ghritam

Content	Latin/English name	Proportion
Durva (swarasa)	<i>Cynodon dactylon</i> Linn.	3.072 l
Yashtimadhu (kalka)	<i>Glycyrrhiza glabra</i> Linn.	64 g
Goghrita	Cow ghee	768 g
Godugdha	Cow Milk	768 ml

DISCUSSION

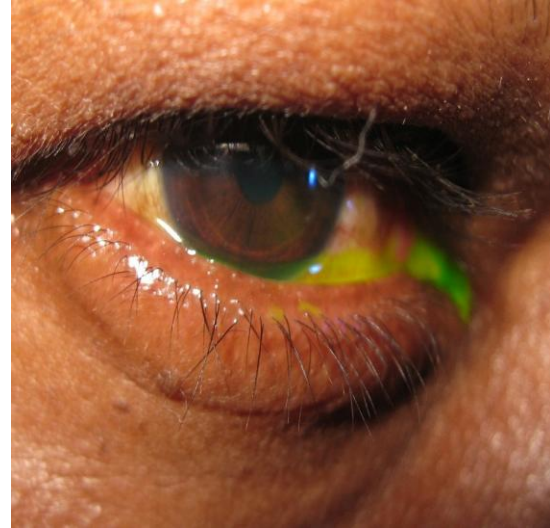
Management of corneal injury entirely varies in Nija (due to internal ocular diseases) and Agantuja variety (due to trauma). Nija variety surely deserves Virechana and Raktamokshana to pacify locally provoked Pitta and Rakta. The present case being Abhighataja, it is not necessary to do the Virechana and Raktamokshana treatment. If injury is not accompanied with other structures of eye but restricted to cornea and not much deep, can be restored back with full structural and functional perfection even without any treatment and simply giving rest to the eyes or external application can resolve the condition early with better outcomes.

Figure 1: Photograph of Right eye (Day 1)



Showing positive fluorescein staining test confirming the diagnosis of corneal erosions

Figure 2: Photograph of Right eye (Day 4)



Showing negative fluorescein staining test confirming the complete healing of corneal erosions

Drugs used to prepare Durvadi Ghrita are having dominantly Madhura Rasa, Sheeta Virya and Madhura Vipaka.^{[7][8]} Because of these properties it is Vata-Pittashamana.^[9] Madhura Rasa is Sandhanakara and Akshiprasadana.^[10] The Anurasa of Durva which are Tikta and Kashaya are Pittashamaka with Krimivishahara (may be antibiotic) and Ropana (healing) properties respectively.^[11] The combination of Honey with Ghrita is indicated in Sadyovrana (fresh wounds) for reducing the Ushma (heat) of Vrana (wound) and for Vranasandhana (wound healing),^[12] hence may be more effective in healing of corneal erosions. *Cynodon dactylon* (Durva) is a known antimicrobial, antiviral^[13] and antiulcer^[14] drug. Ghee alone or in combination with honey^[15] is considered to be extremely useful for treating wounds, inflammatory swellings and blisters for promotion of quick healing.^[16] Cow Ghee is a rich sources of essential fatty acids, such as Omega-3 and Omega-6 which regulate prostaglandin synthesis and hence induce wound healing and thus important for the maintenance of normal epidermal structure.^{[17][18]} *Glycyrrhiza glabra* Linn.

(Yastimadhu) has been shown to inhibit the activity of pro-inflammatory prostaglandins and leukotrienes, and appears to have a cortisone-like effect making it useful as an anti-inflammatory.^[19] Visual acuity has improved rapidly which may be attributed to the complete resolution of corneal erosion and circumcorneal congestion.

Beside this pharmacological efficacy, the application of Durvadi Ghrita causes a shield over cornea that prevents further infection and keeps maintaining the moistening of cornea, which prevents the mechanical damage to the cornea. It is cost effective than conventional eye drops or ointments used for treatment. This case study points towards vanishing all the misconcepts regarding the efficacy and safety of Ayurvedic local applications in corneal erosions. However, proper clinical trials in large samples are needed to substantiate the observations, so that it can replace or be integrated with conventional care.

REFERENCES

1. <http://emedicine.com/emerg/topic736.htm>. [Accessed on 8 December 2008]
2. http://www.emedicinehealth.com/chemical_eyeburns/article_em.htm. [Accessed on 8 December 2008]
3. <http://emedicine.medscape.com/article/1215950-overview#a0199> [Accessed on 12 July 2012]
4. Sushruta. Sushruta Samhita, Jadavaji Trikamji Acharya, editor. 7th ed. Varanasi: Chaukhamba Orientalia; 2002. Uttaratantra 6/5.p.602.
5. Kheirkhah A, Johnson DA, Paranjpe DR, Raju VK, Casas V, Tseng SC. Temporary sutureless amniotic membrane patch for acute alkaline burns. Arch Ophthalmol. 2008;126(8):1059-66.
6. Sharangadhara. Sharangadhar Samhita, Brahmananda Tripathi, editor. Varanasi: Chaukhamba Orientalia; 2008. Madyama khanda1/9. p.218.
7. Bapalal Vaidya. Nighantu Adarsha, Vol. 2. Varanasi: Chaukhamba Bharati Academy, Varanasi; 2007. p.717.
8. Ibid. p.435.
9. Vagbhata. Ashtanga Hridaya, Hari Sadasiva Sastri, Paradakara Bhisagacharya, editors. Varanasi: Chaukhamba Orientalia; 2007. Sutrasthana 1/15. p.11.
10. Ibid. Sutrasthana 10/ 2 and 8. p.174-175.
11. Ibid. Sutrasthana 10/14-20. p.49.
12. Sushruta. Sushruta Samhita, Yadavaji Trikamji Acharya, editor. 7th ed. Varanasi: Chaukhamba Orientalia; 2002. Chikitsasthana 1/130. p.407.
13. Santosh Kumar Singh, Prashant Kumar Rai, Dolly Jaiswal, and Geeta Watal. Evidence-based Critical Evaluation of Glycemic Potential of *Cynodon dactylon*. Evid Based Complement Alternat Med 2008; 5(4): 415-420.
14. Patil MB, Jalalpure SS, Prakash NS, Kokate CK. Antiulcer properties of alcoholic extract of *Cynodon dactylon* in rats. Acta hort 2005; 680:115-118.
15. Simon A, Traynor K, Santos K, Blaser G, Bode U, Molan P. Medical honey for wound care-still the latest resort. Evid Based Complement Alternat Med 2009; 6(2):165-173.
16. Hema Sharma Datta, Shankar Kumar Mitra, Bhushan Patwardhan, Wound Healing Activity of Topical Application Forms Based on Ayurveda. Evid Based Complement Alternat Med 2011. (Article ID: 134378, doi:10.1093/ecam/nep015)
17. Merkel DR. Omega-6 oils: significance in cosmetics. In Cosmetics Proceedings. Frankfurt, Germany; 1992.p.162-178.
18. Connor WE. Importance of n-3 fatty acids in health and disease. American Journal of Clinical Nutrition 2000; 71(1):171-175.
19. Okimasu E, Moromizato Y, Watanabe S. Inhibition of phospholipase A2 and platelet aggregation by glycyrrhizin, an anti-inflammation drug. Acta Med Okayama 1983;37(5):385-91.

Source of Support: Govt. Ayurveda college, Tripunithura

Conflict of Interest: None Declared